




**PRAIRIE LIVESTOCK**  
V E T E R I N A R I A N S

# Introduction to Poultry Anatomy

Dr. Teryn Girard  
November 17, 2021

# Normal External Bird Anatomy



# Normal vs. Abnormal External Bird Anatomy



Comb

Beak

Wattle



Shank

Hock

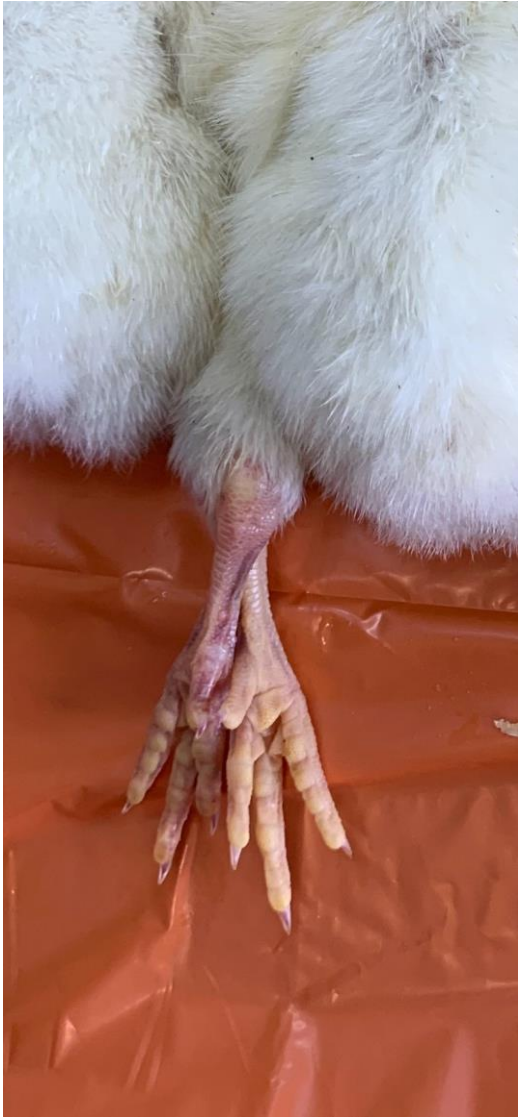


PLV


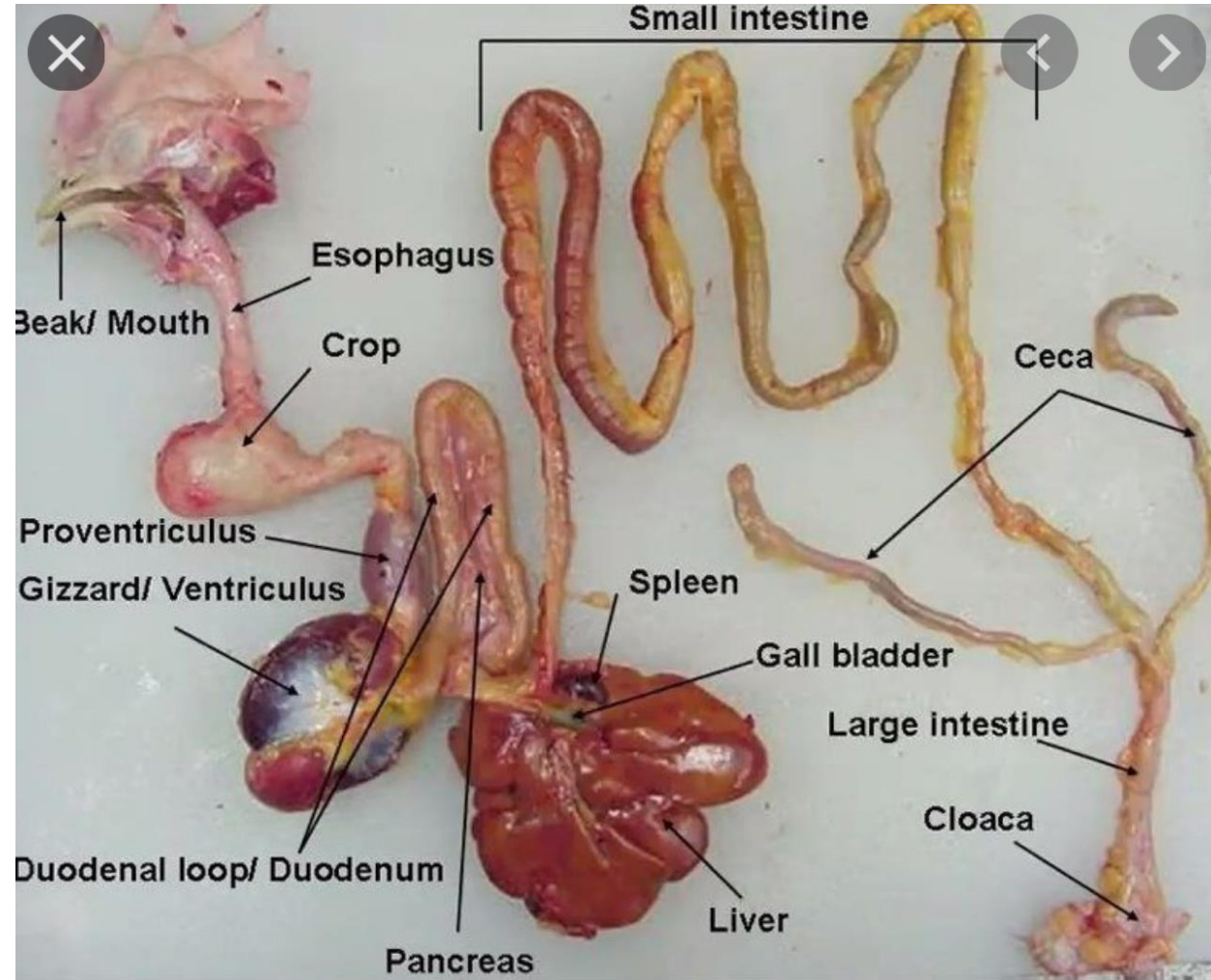
# Normal Vs. Abnormal External Bird Anatomy



# Normal vs. Abnormal External Bird Anatomy

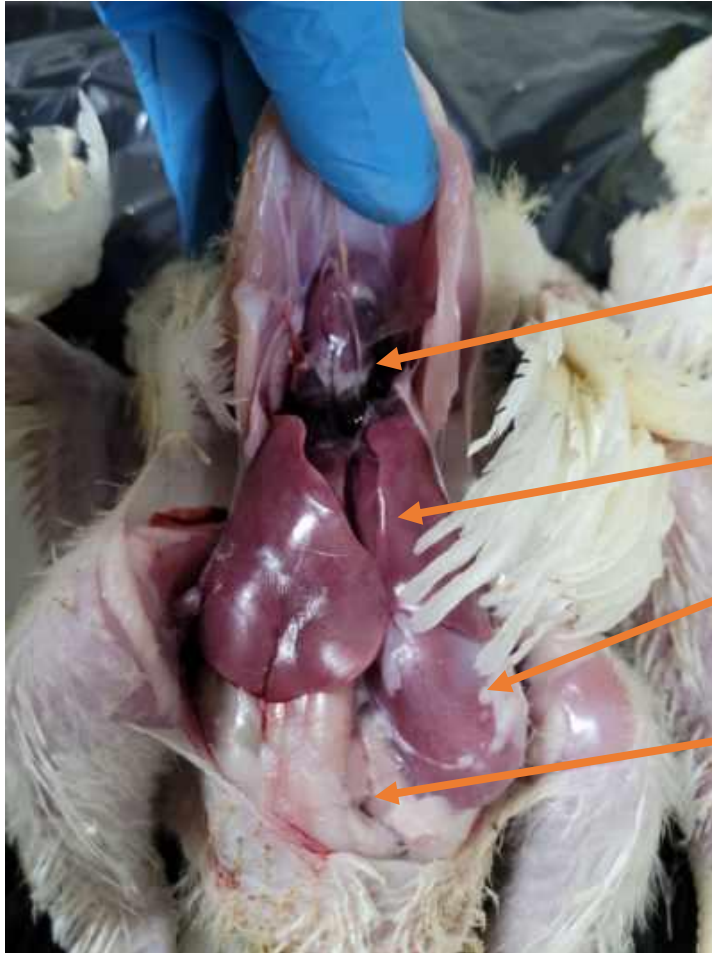


# Internal Bird Anatomy

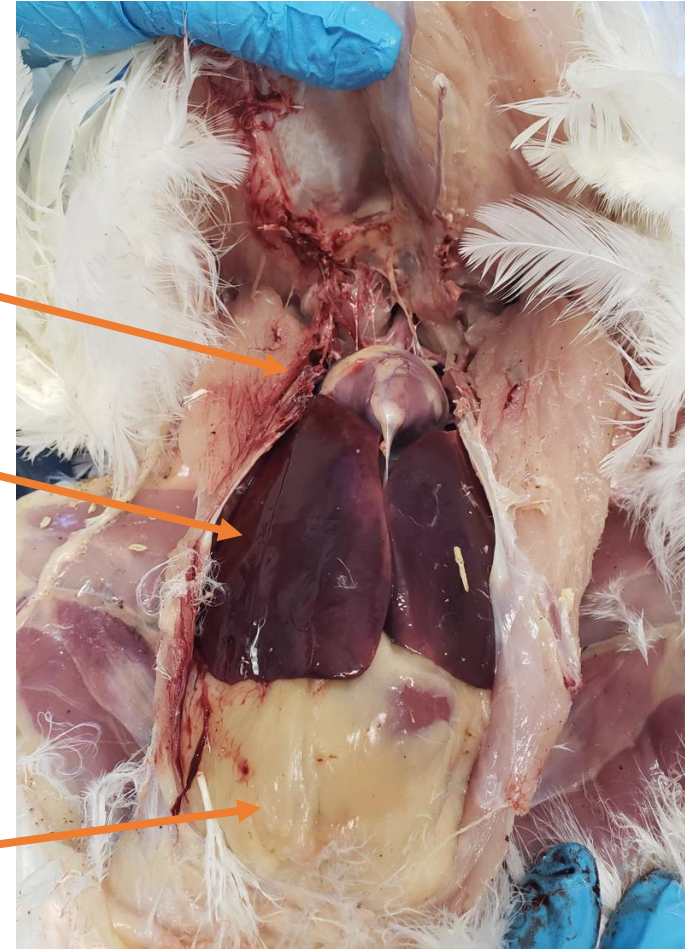


# Normal Abdomen Anatomy

Broiler Chicken



Laying Chicken



Heart

Liver

Gizzard/Ventriculuous

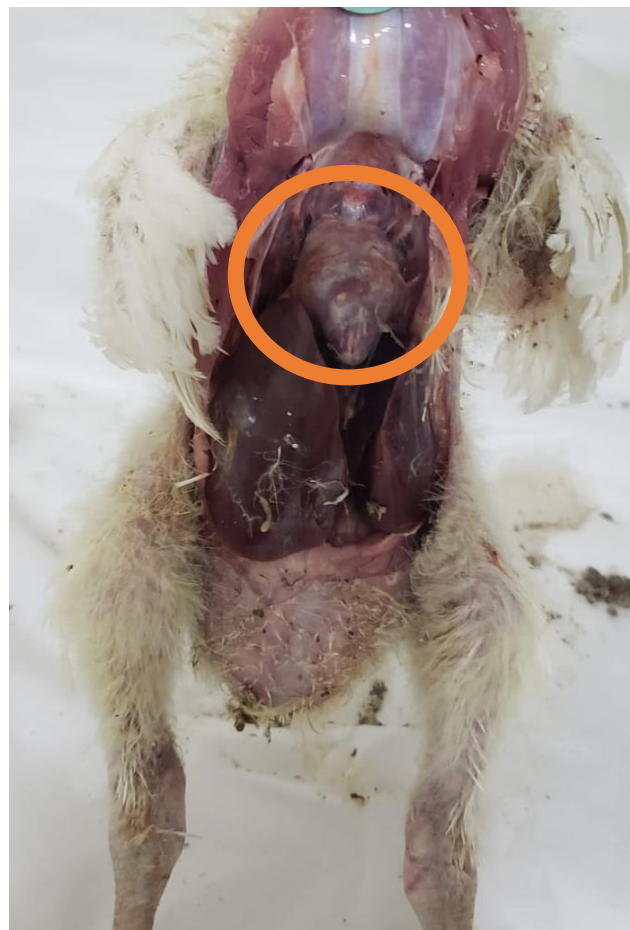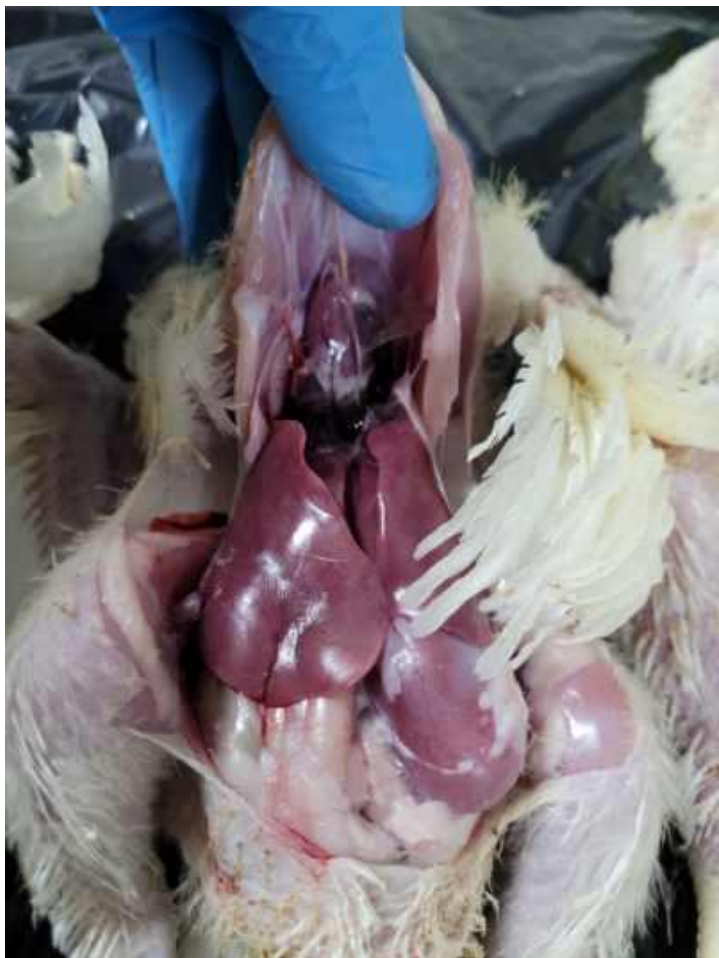Intestines

Fat Pad



PLV

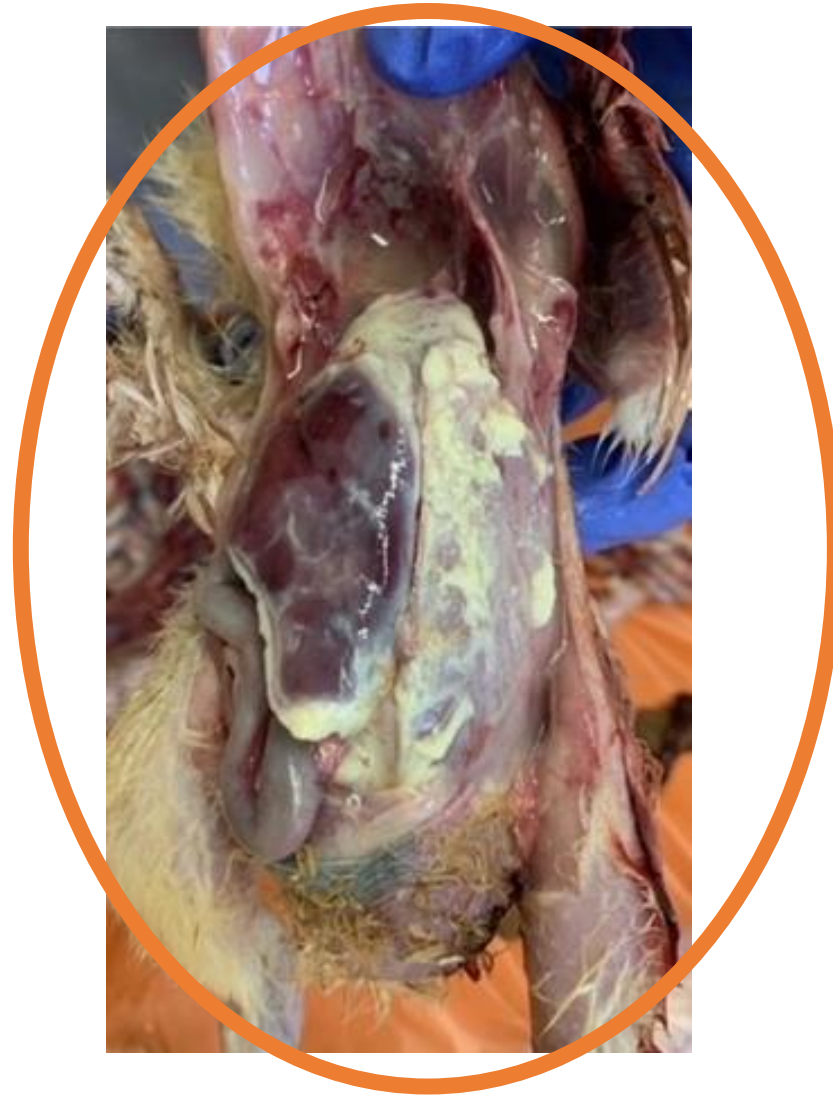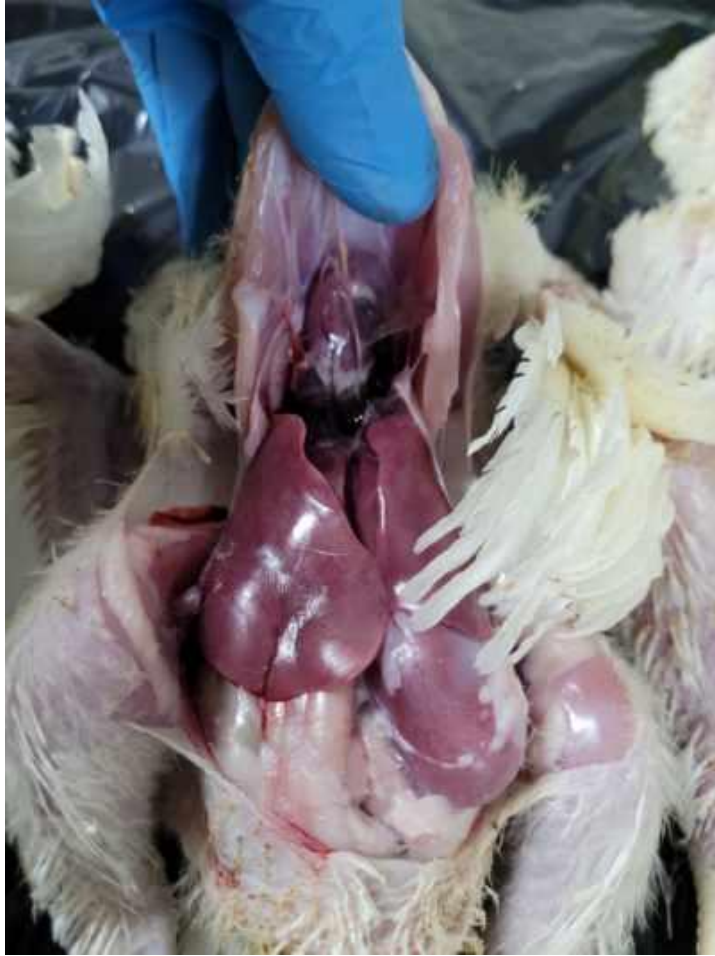# Pericardium



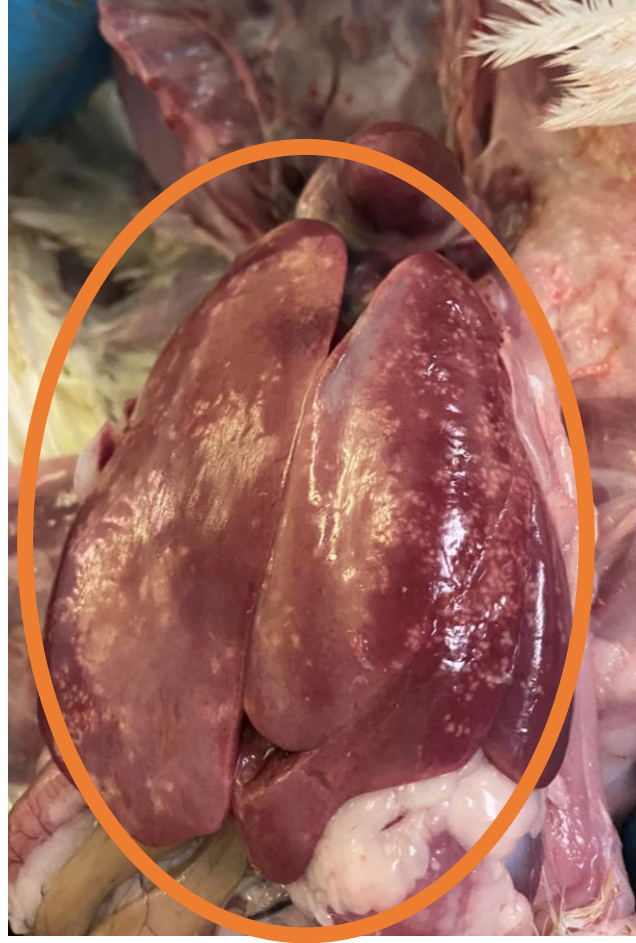PLV



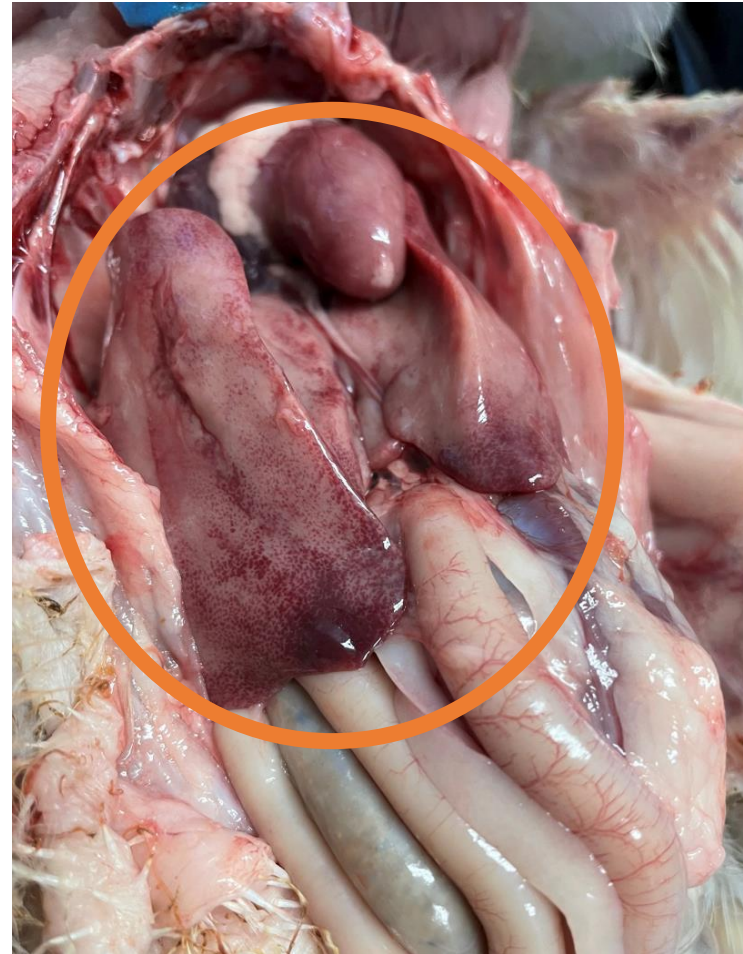
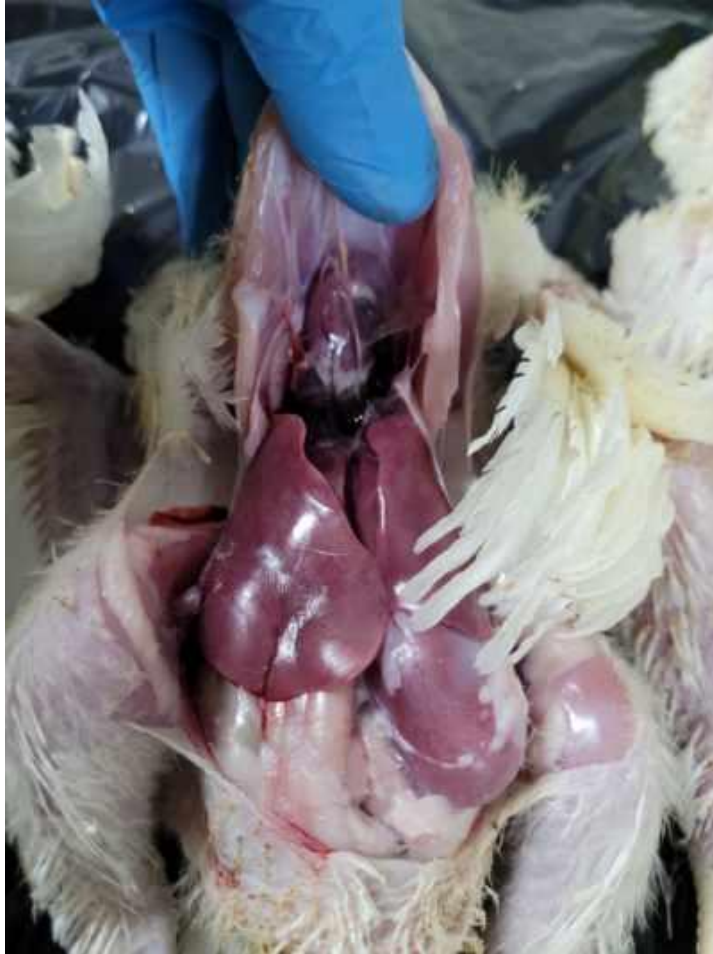# Peritoneum



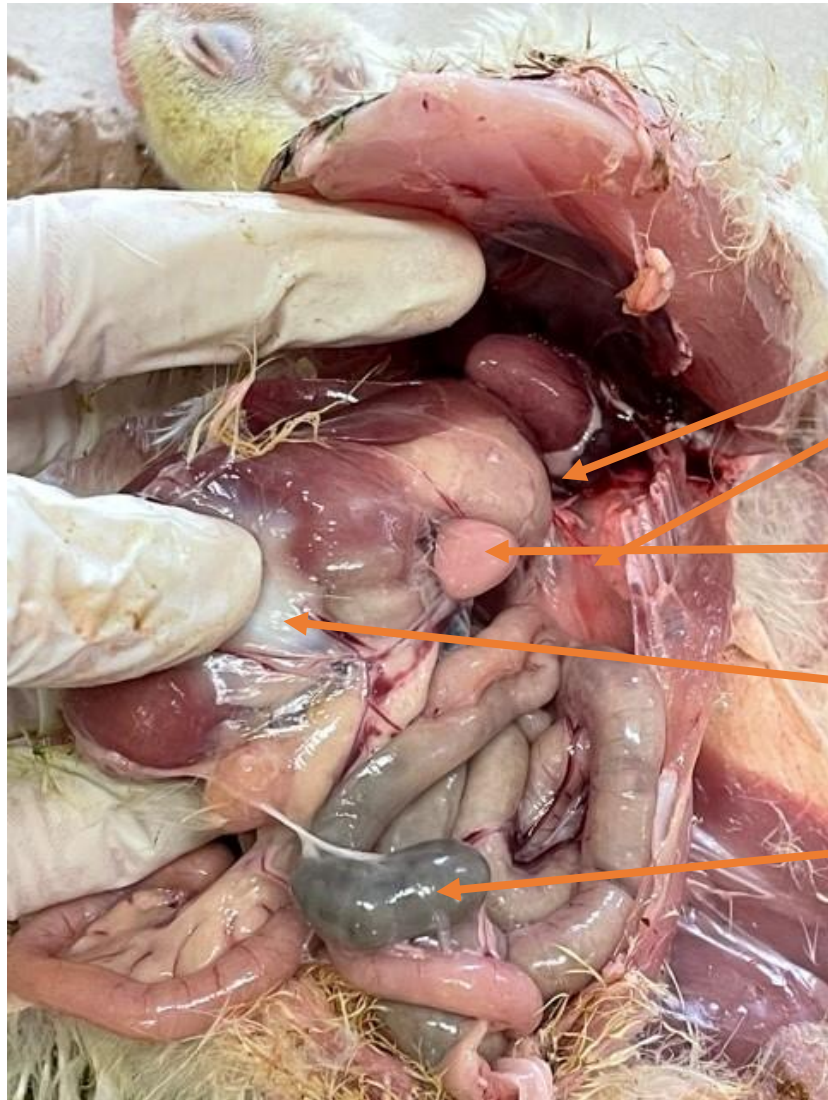
# Liver



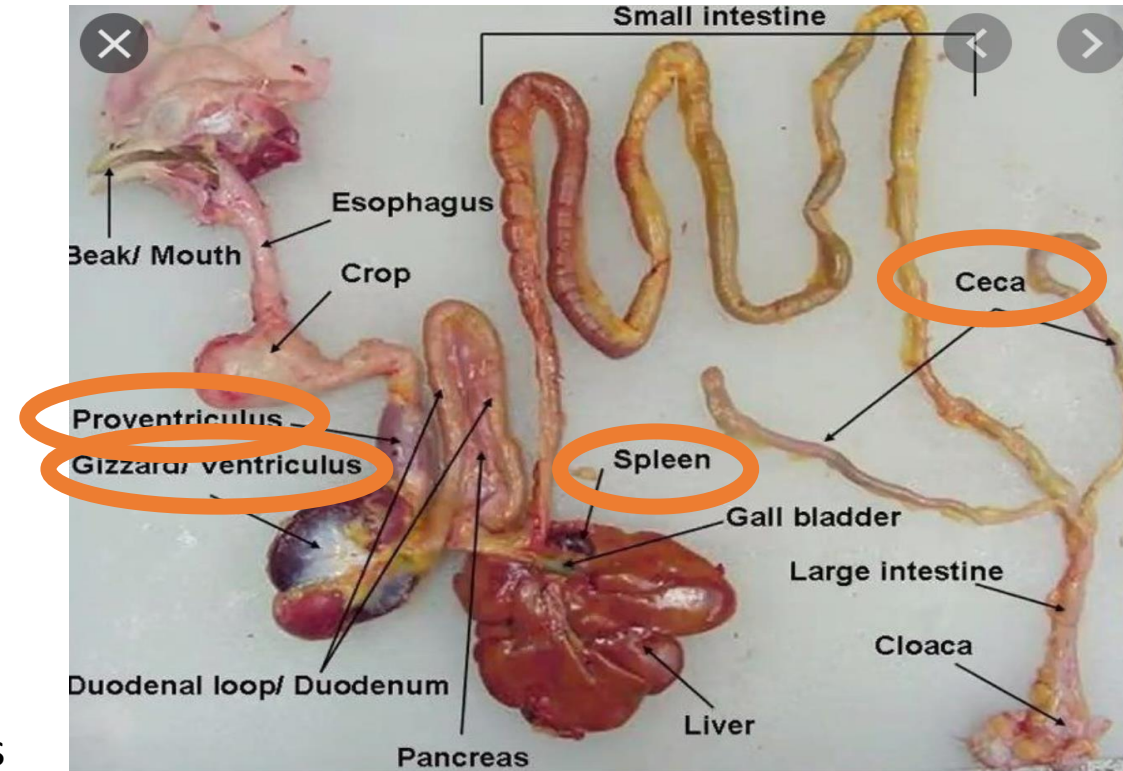
# Liver



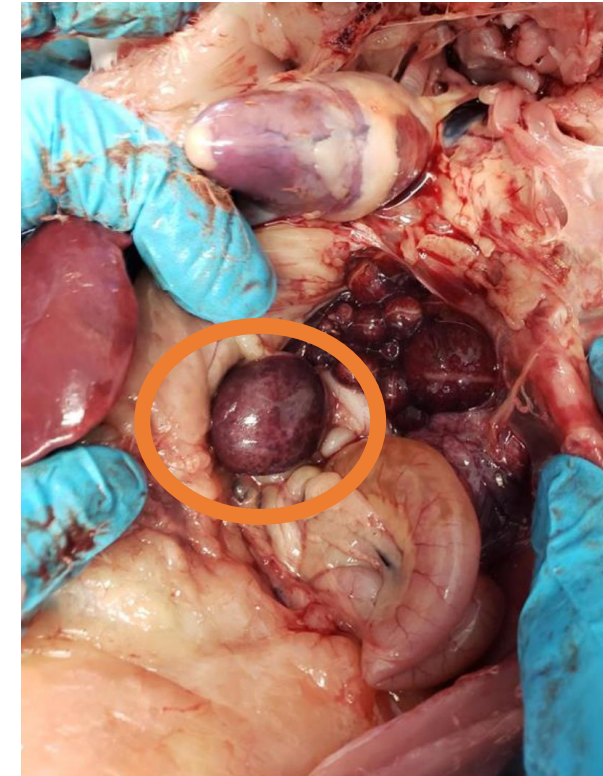
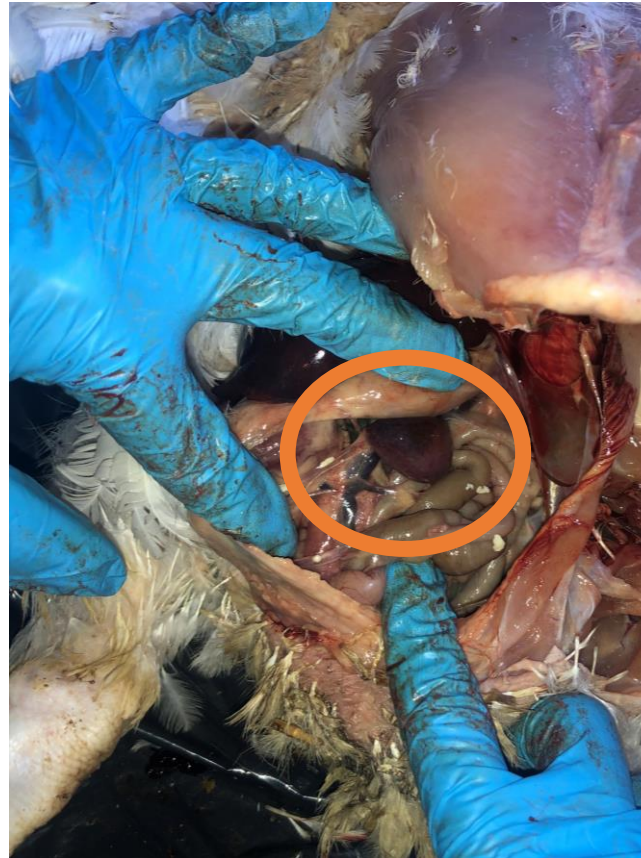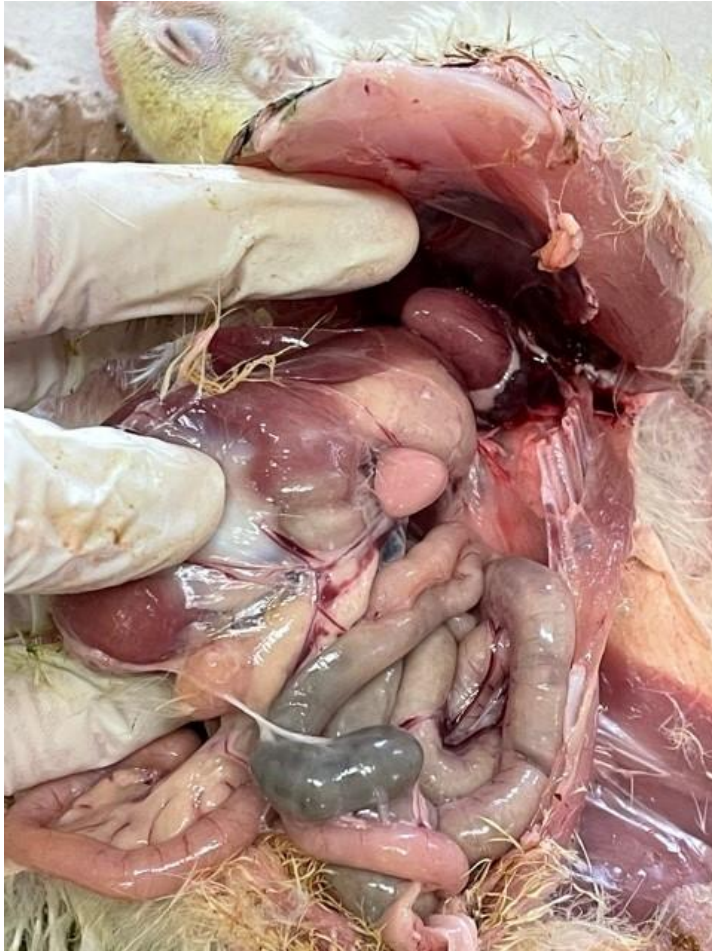# Further Into Internal Anatomy



Proventriculus  
Lung  
Spleen  
Gizzard/Ventriculus  
Ceca

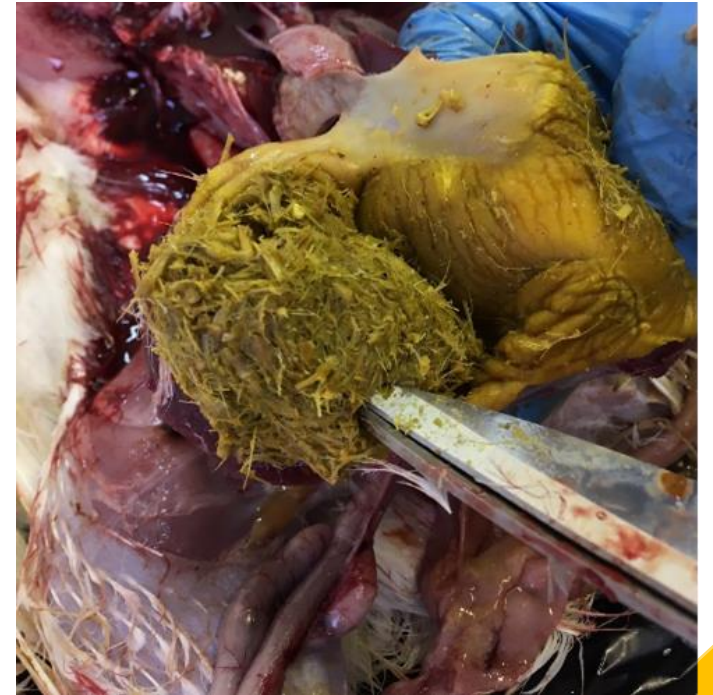
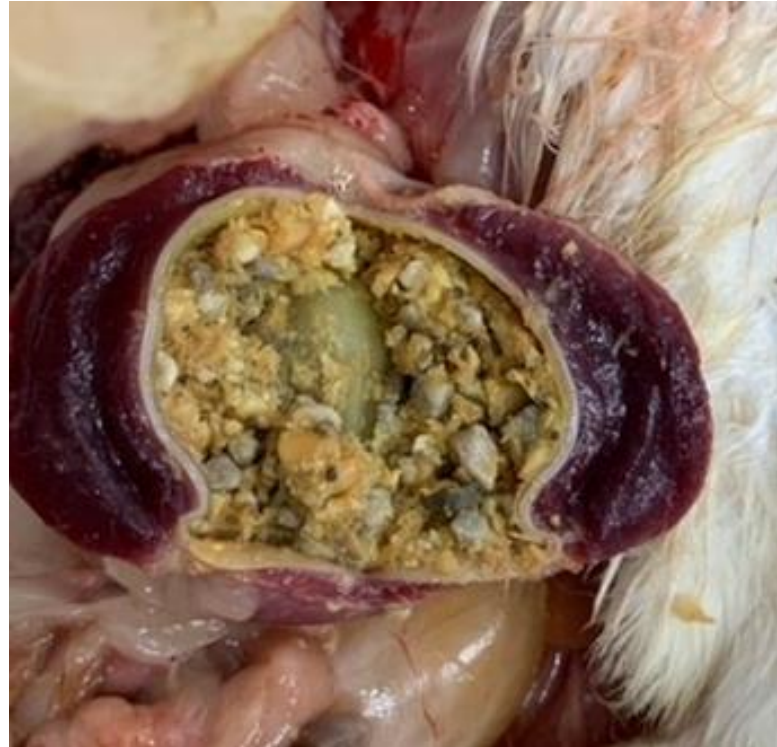
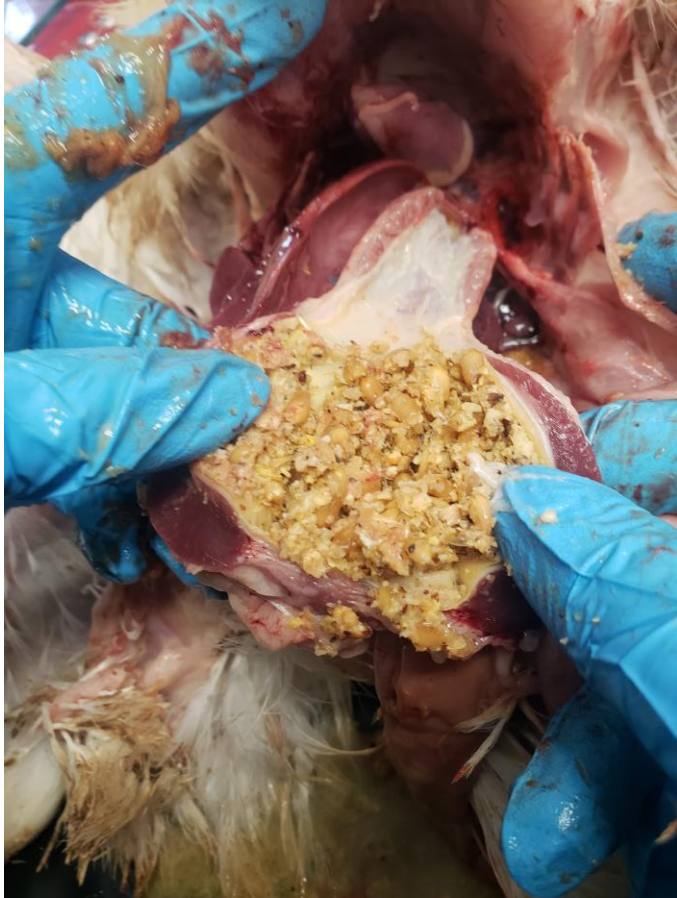# Normal vs. Abnormal Spleen

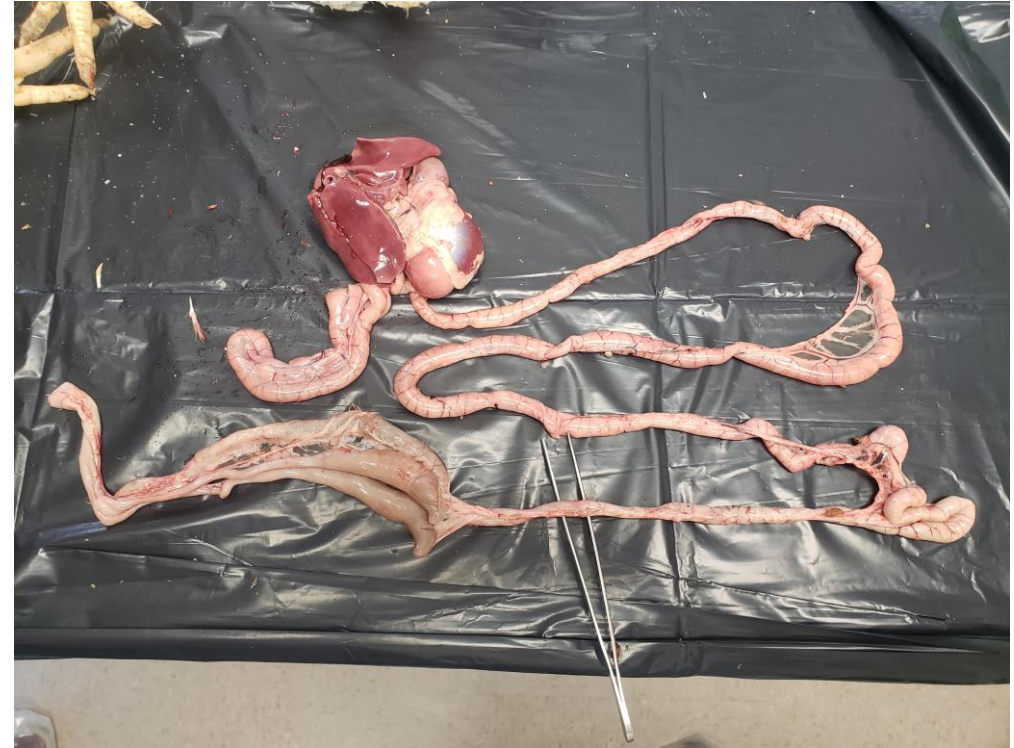
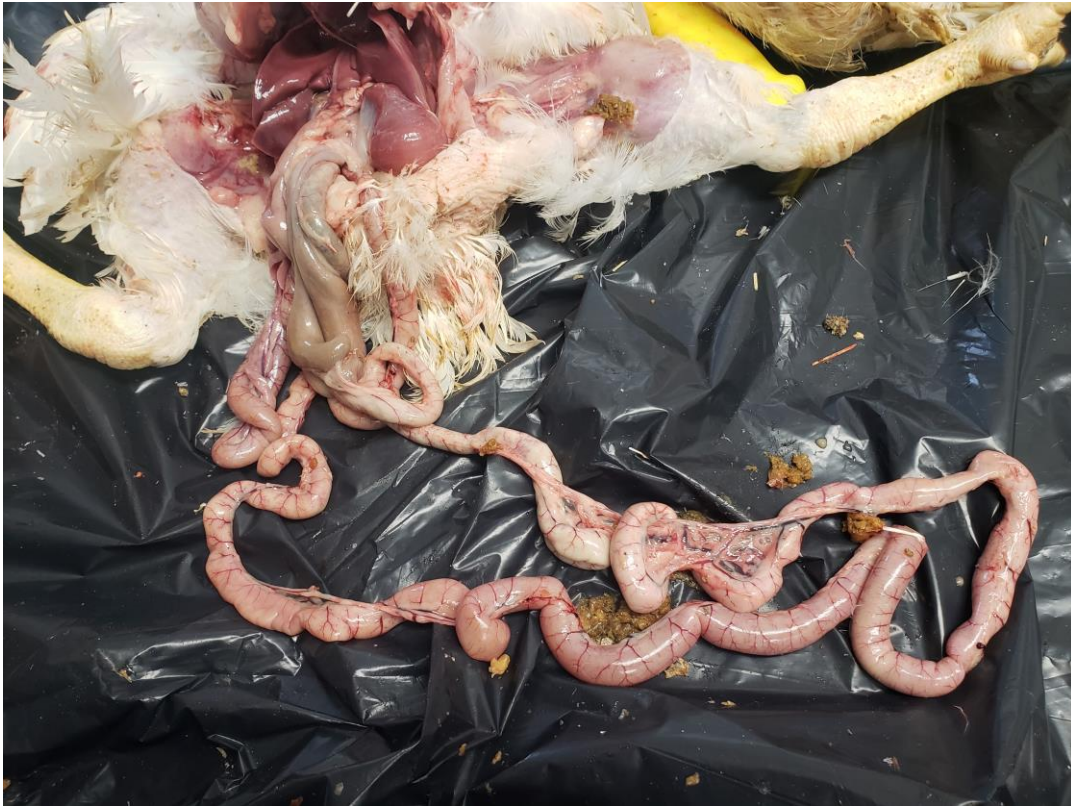
PLV

# Gizzard/Ventriculuous

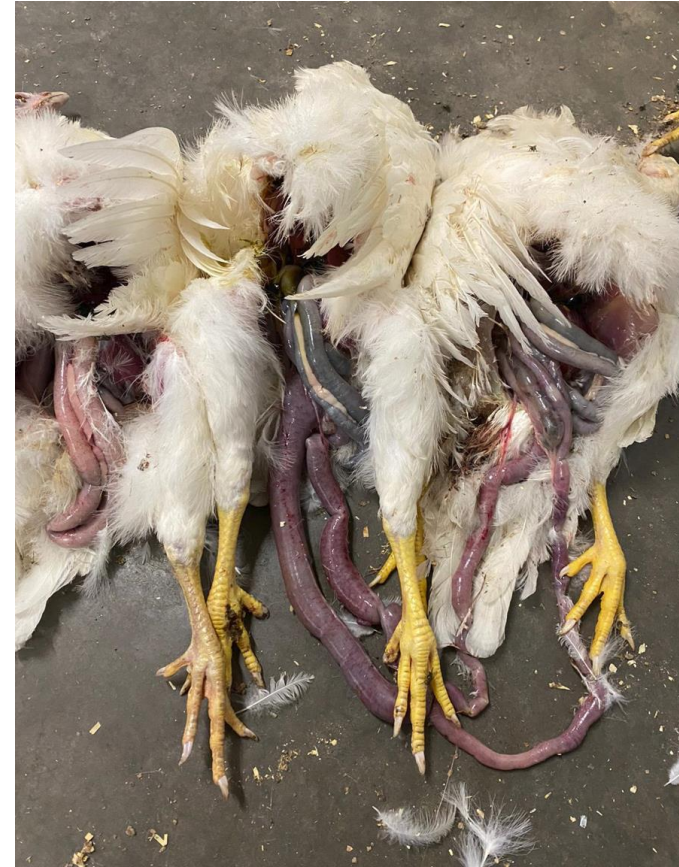
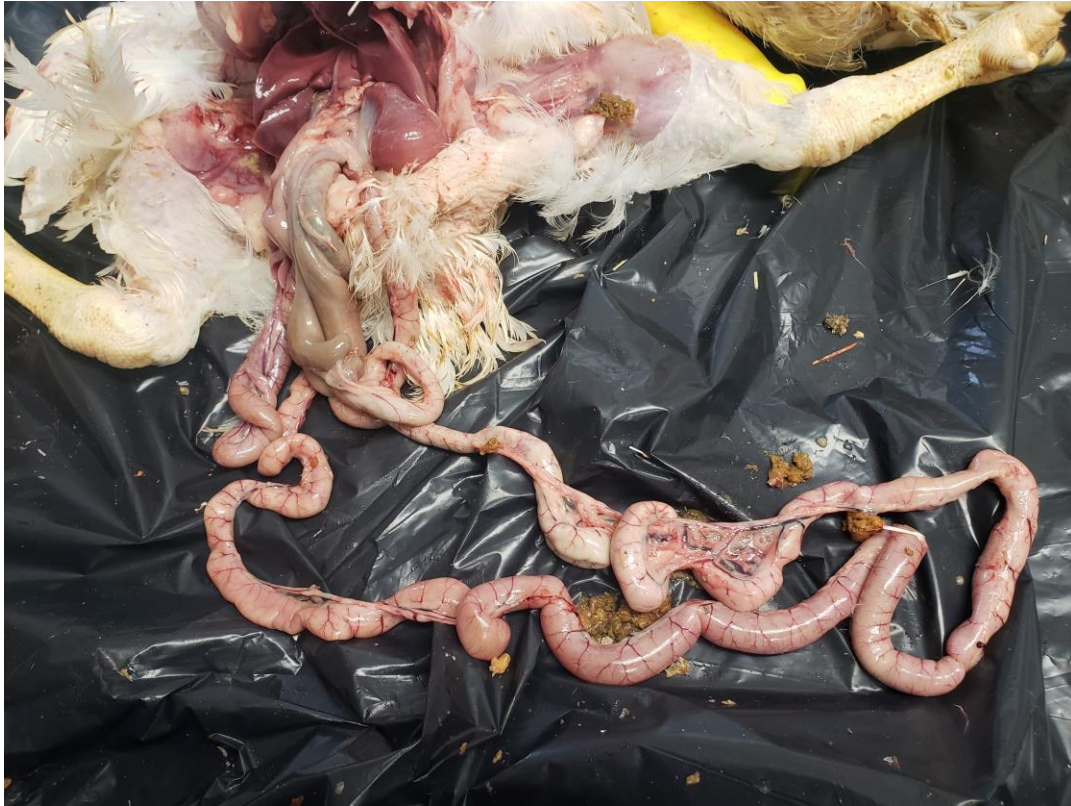
# Normal Intestines



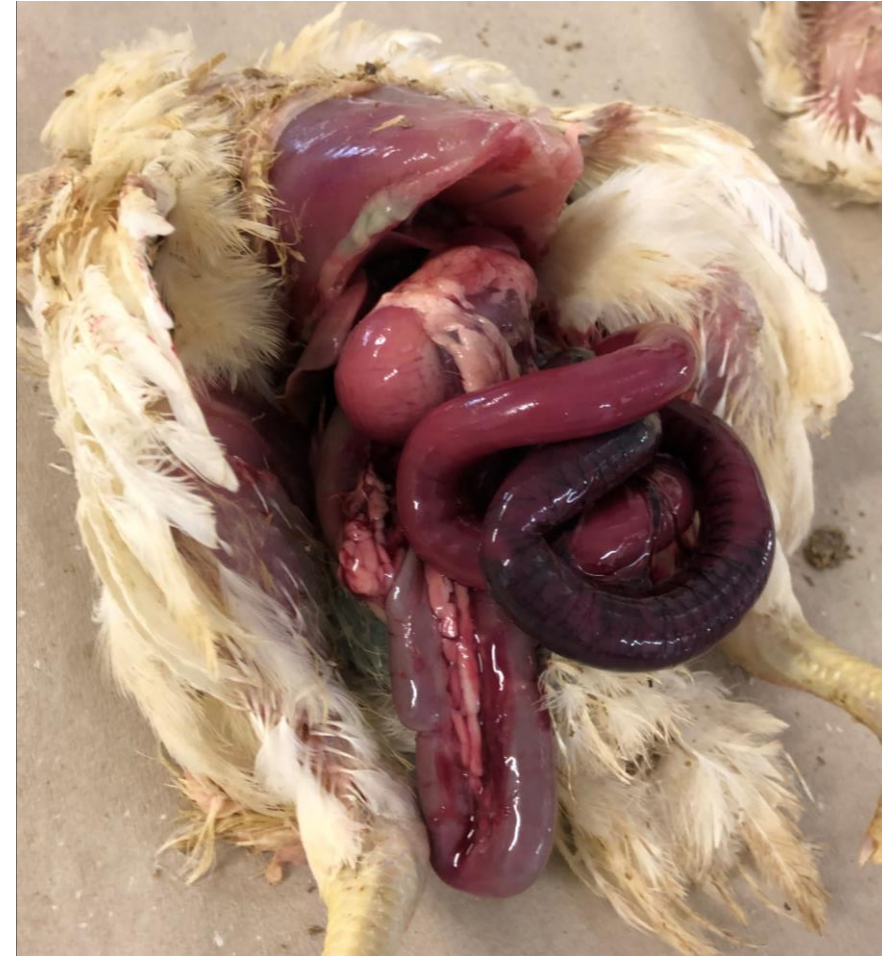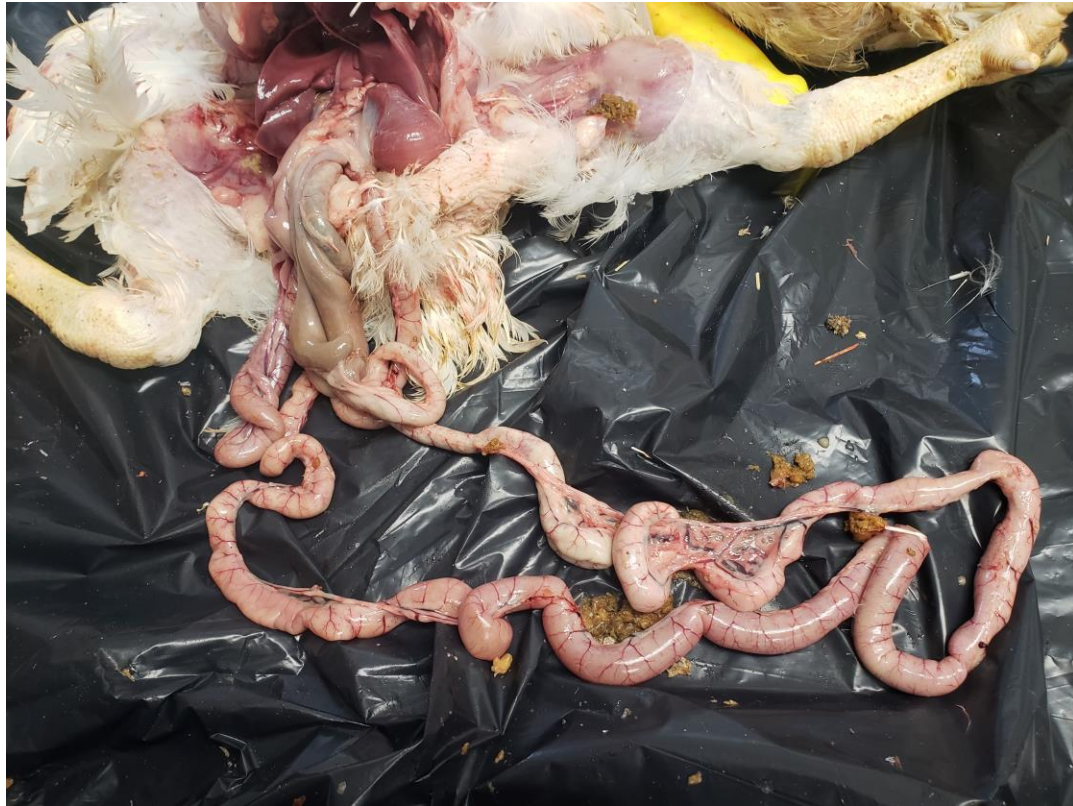PLV

# Normal vs. Abnormal Intestines



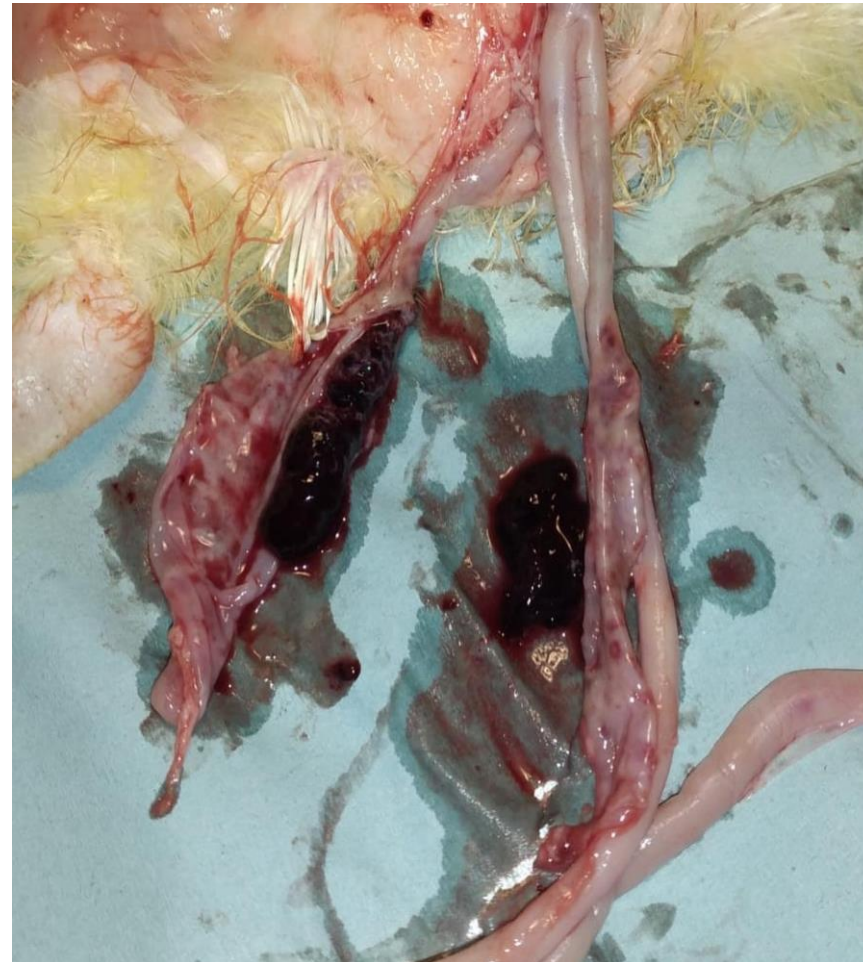
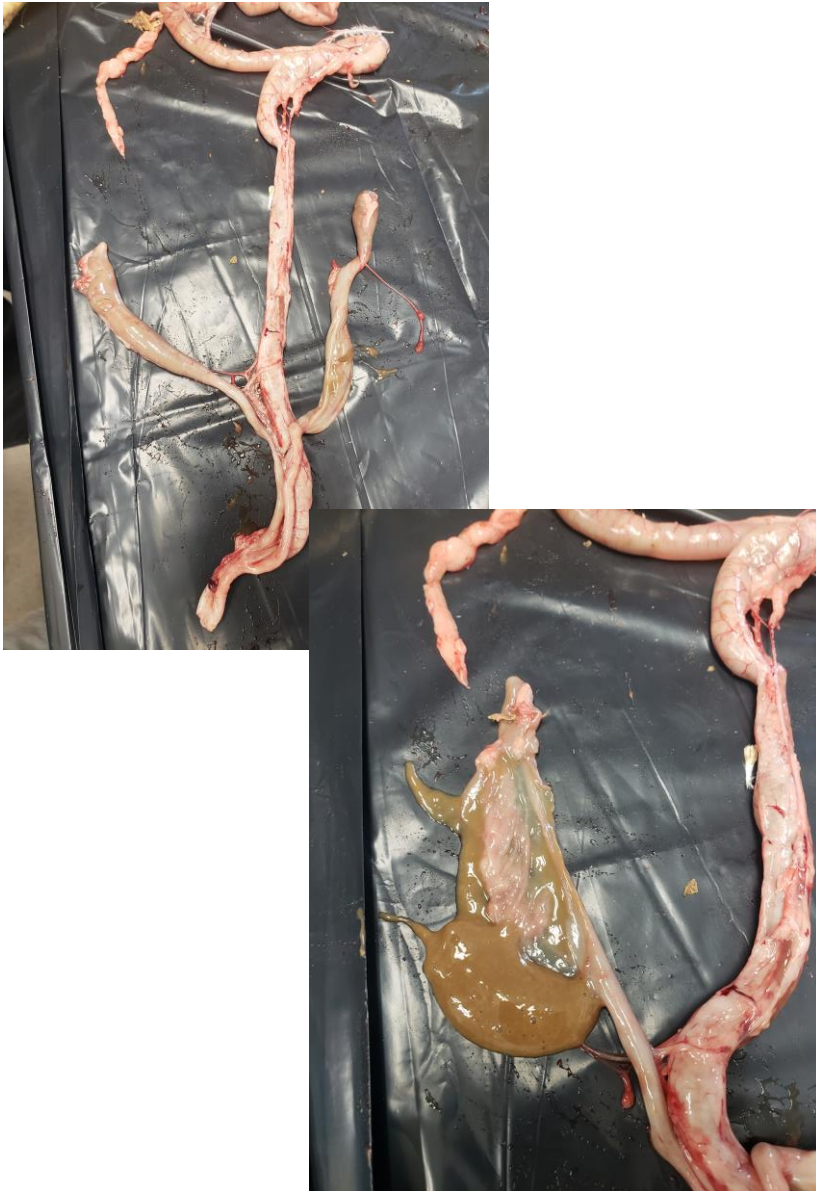
# Normal vs. Abnormal Intestines



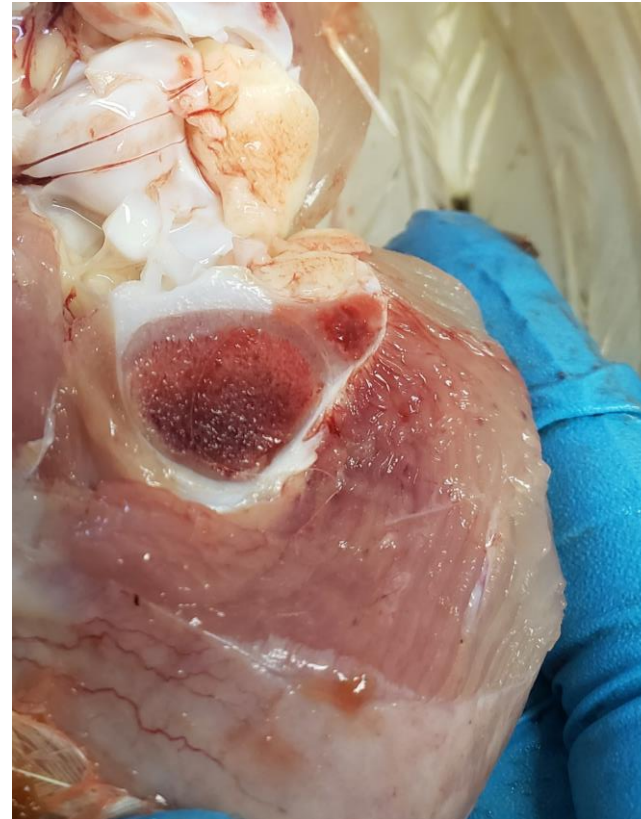
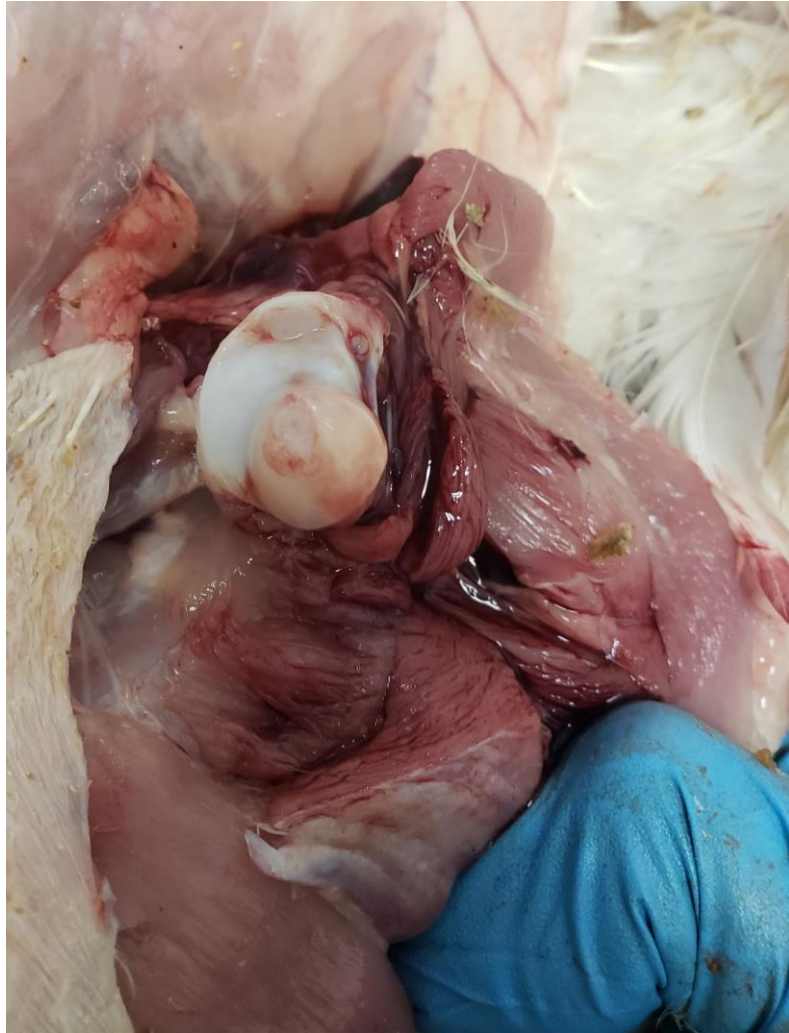PLV

# Normal vs. Abnormal Intestines

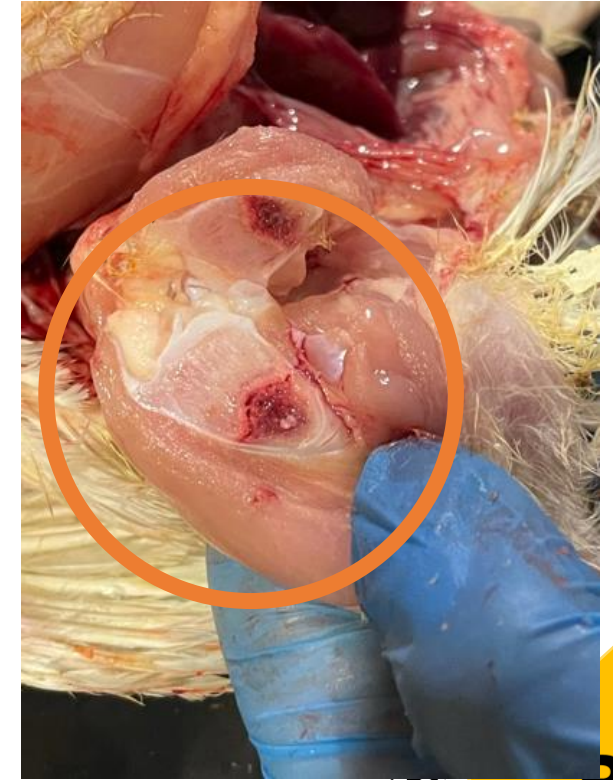
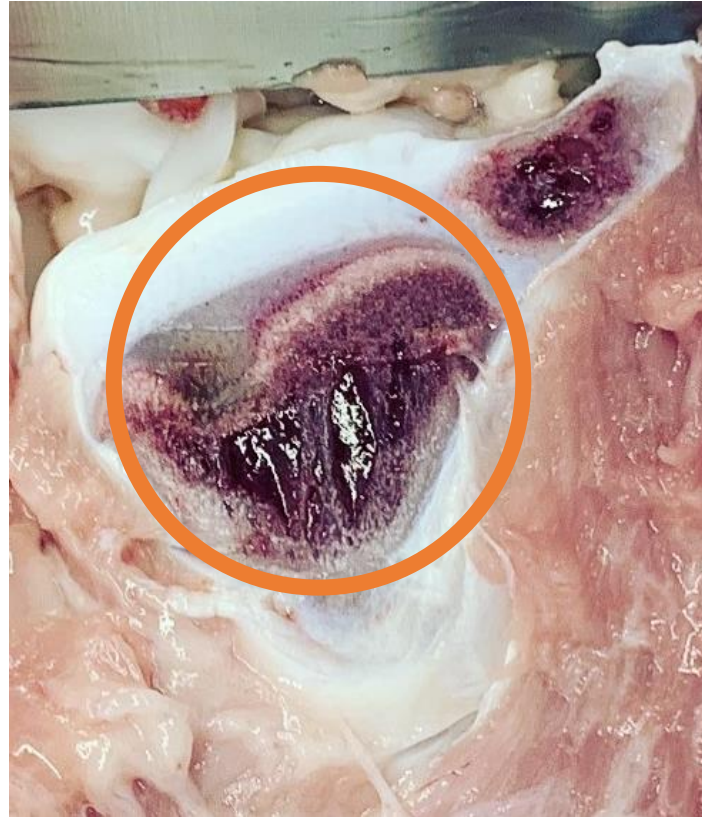
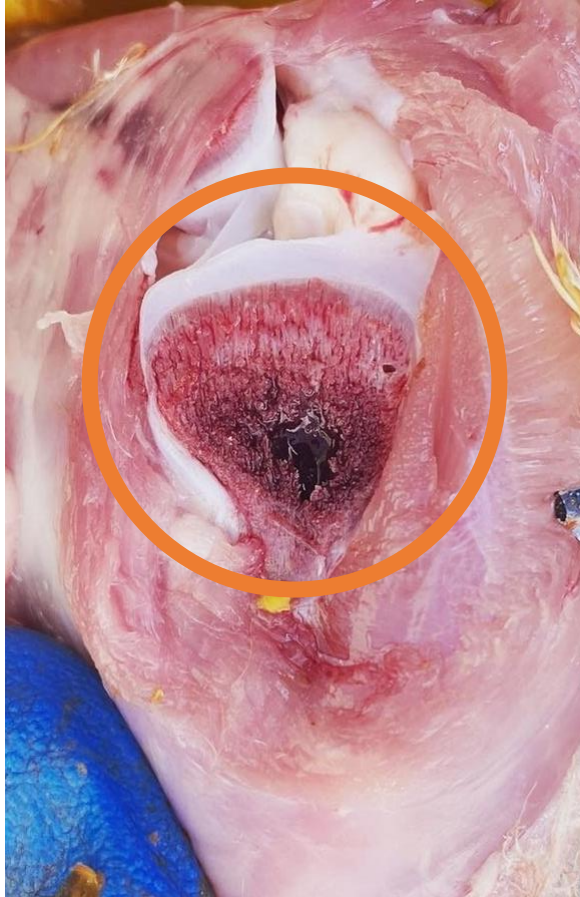PLV

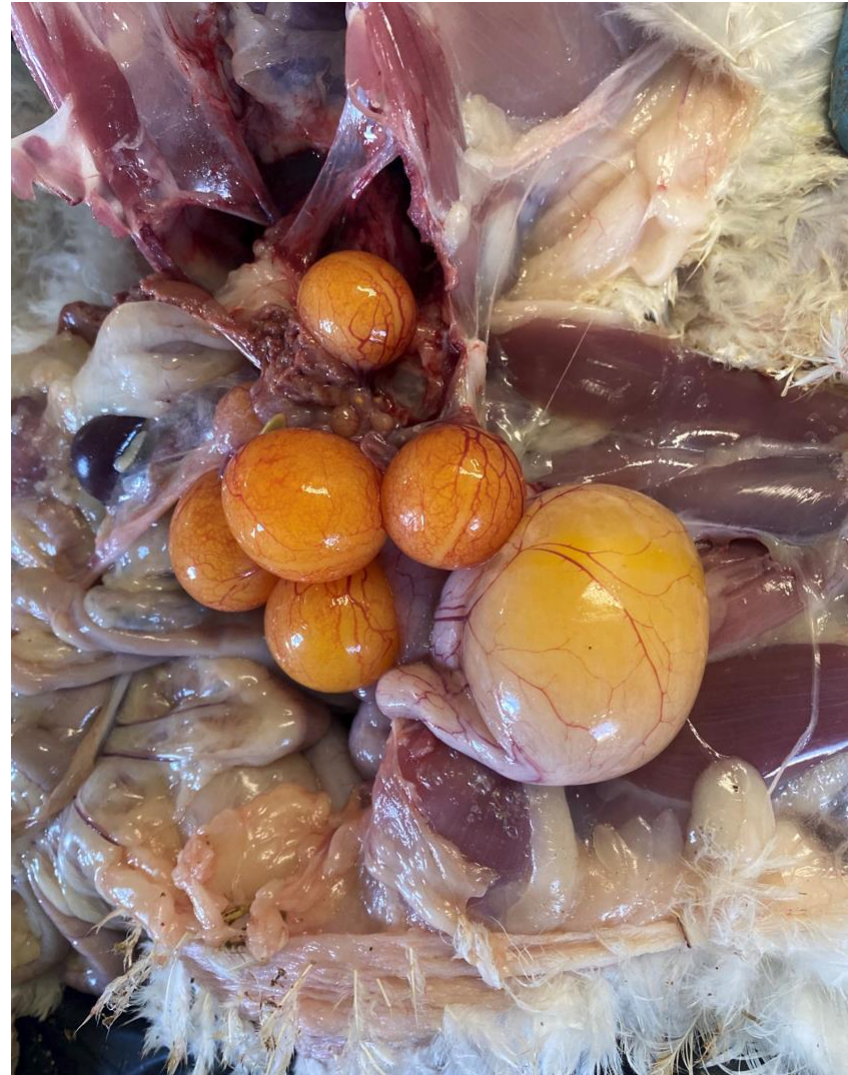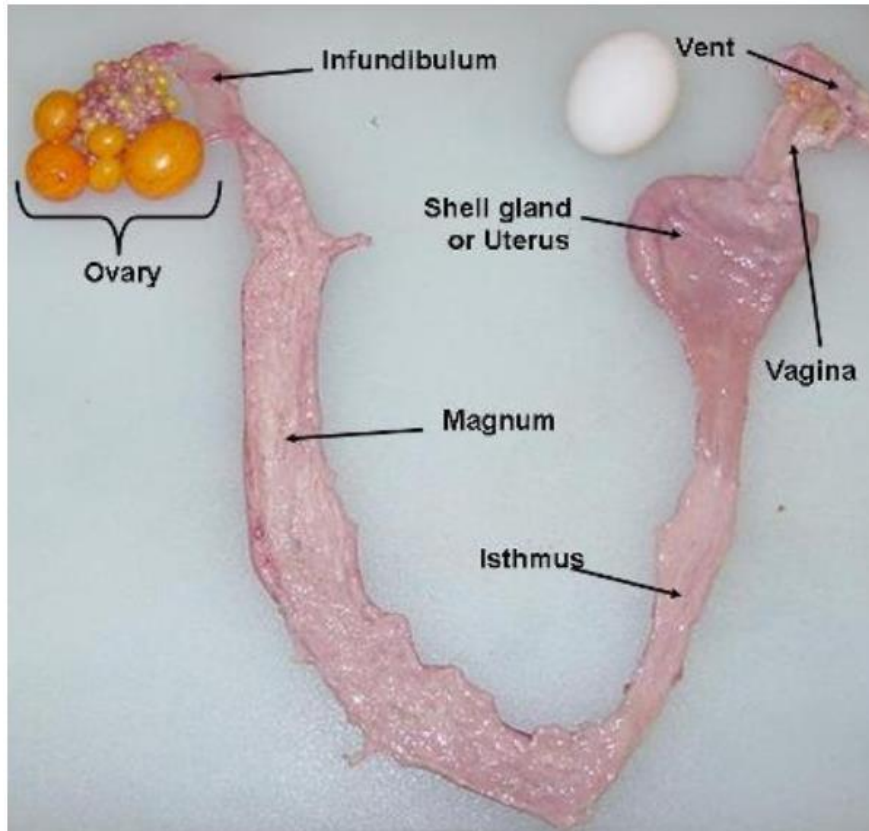
# Meat Birds: Normal Growth Plate and Bone Health



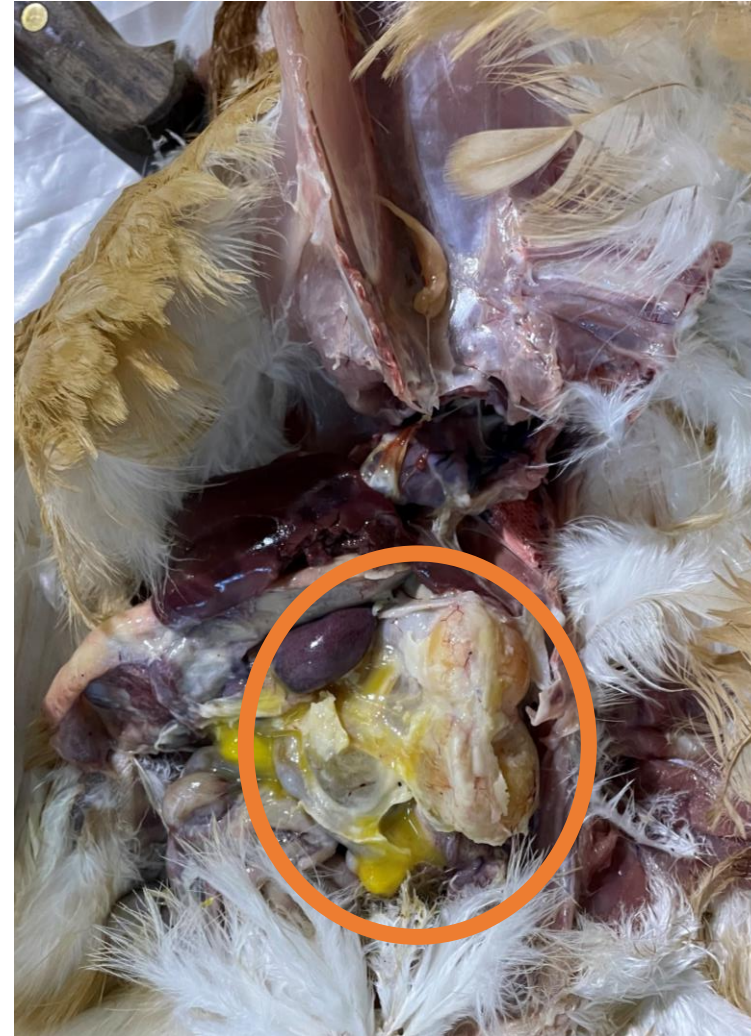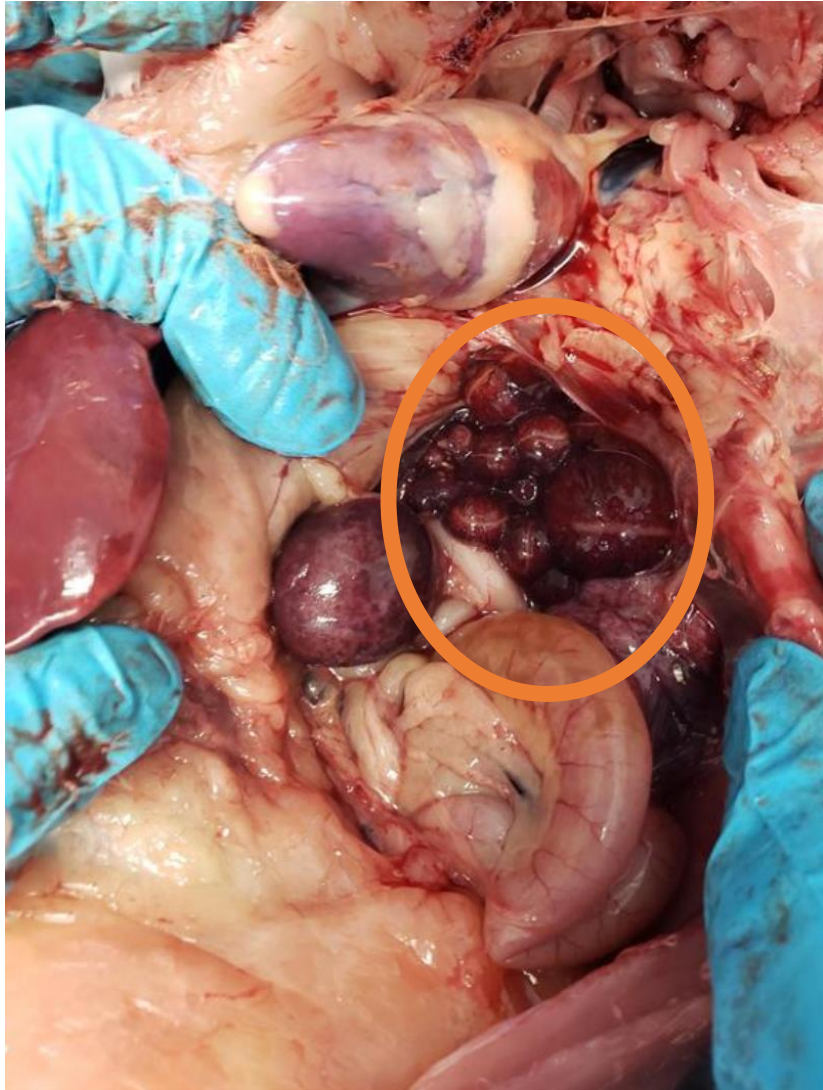
# Meat Birds: Abnormal Growth Plate and Bone Health



# Laying Hens: Reproductive Tract



# Laying Hens: Abnormal Reproductive Tract



THANK YOU!



**PRAIRIE LIVESTOCK**  
V E T E R I N A R I A N S